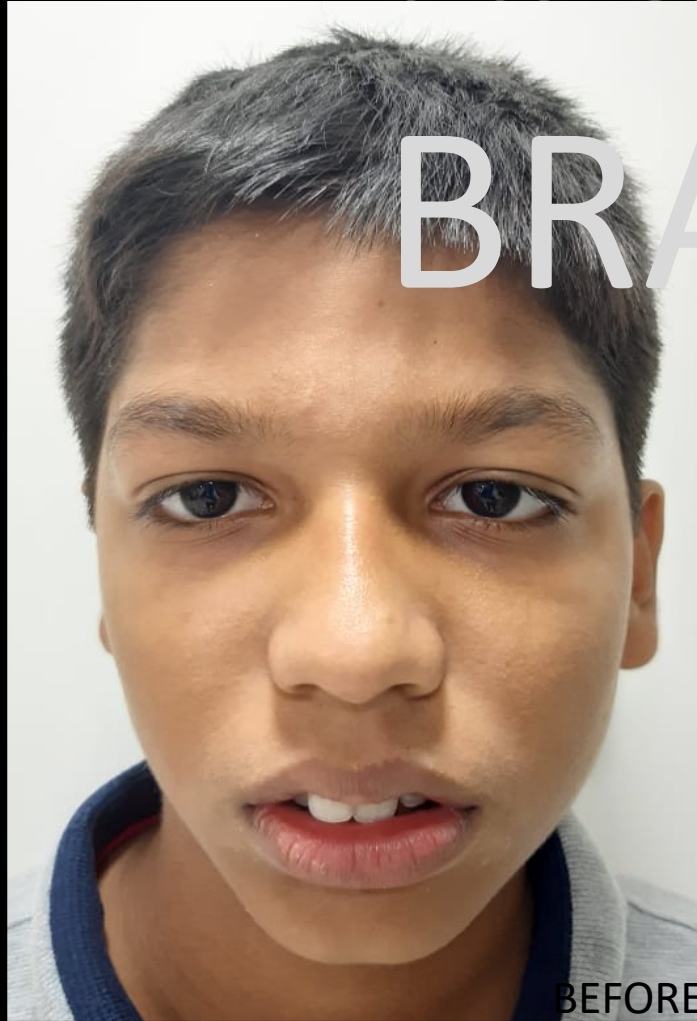


ORTHODONTIC
TREATMENT IN
YOUNG
INDIVIDUAL

TREATED WITH
ALL FIRST
PREMOLAR
EXTRACITONS


HAPPY BRACES





BEFORE TREATMENT

- NOTICE IMPROVEMENT
IN SMILE AND OVERALL
FACIAL APPEARANCE
POST ORTHODONTIC
TREATMENT

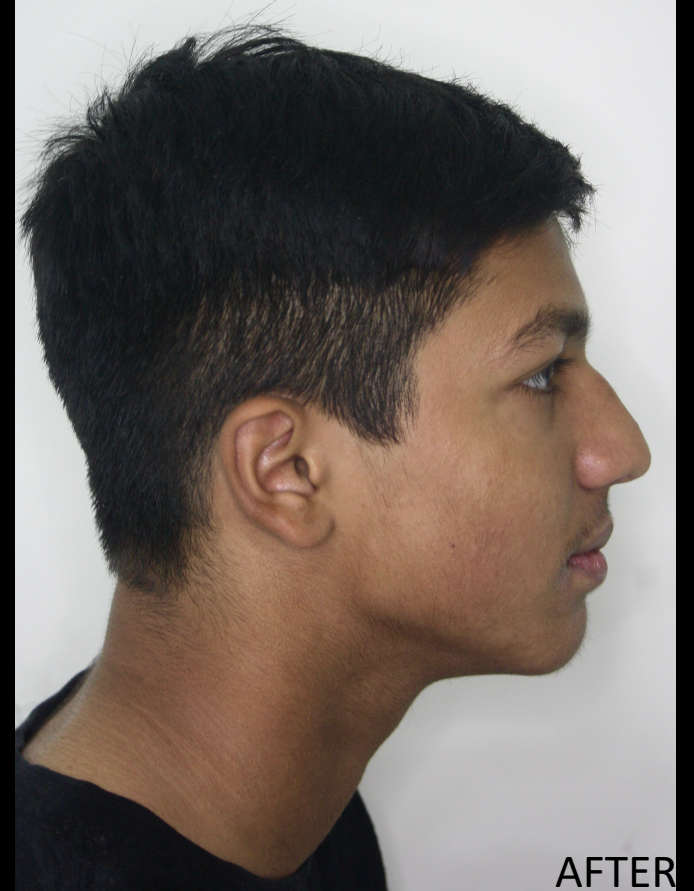

AFTER TREATMENT

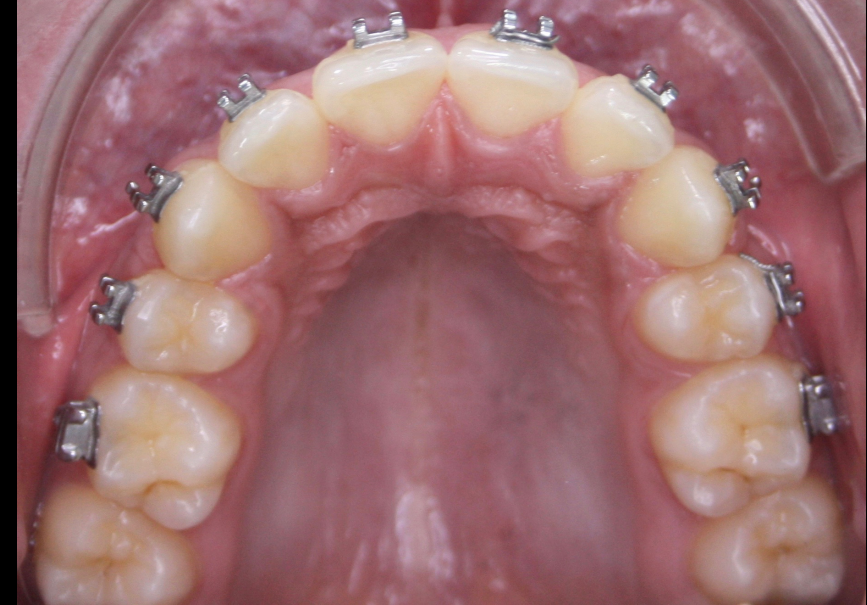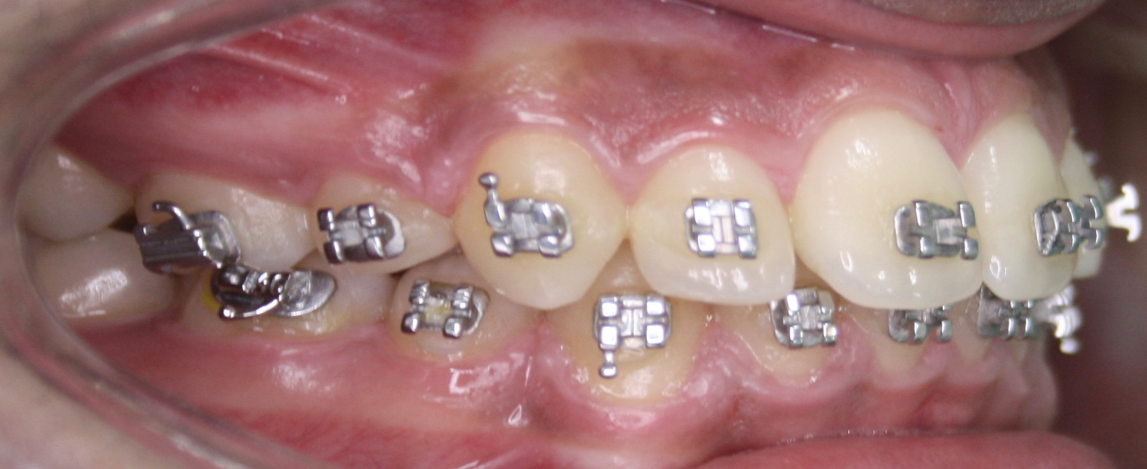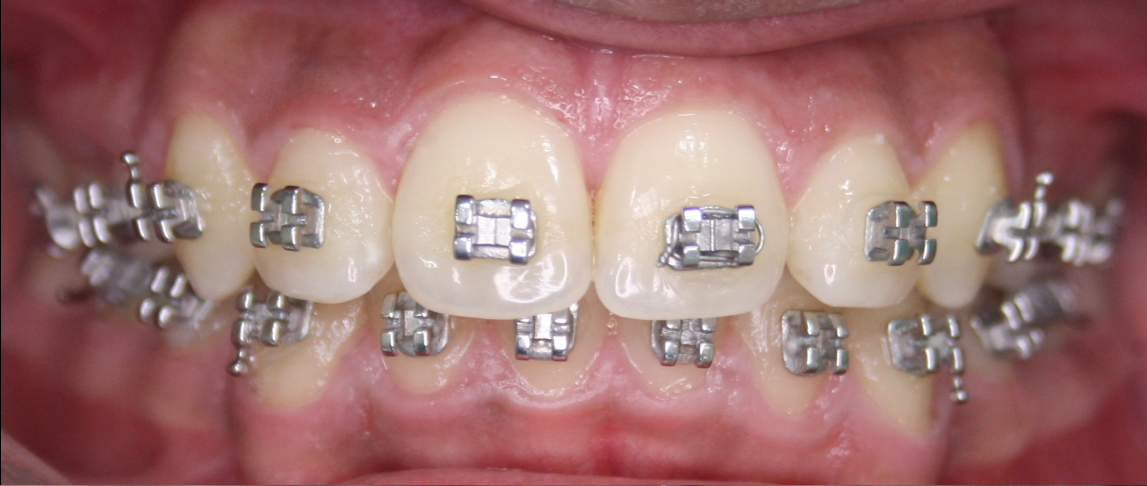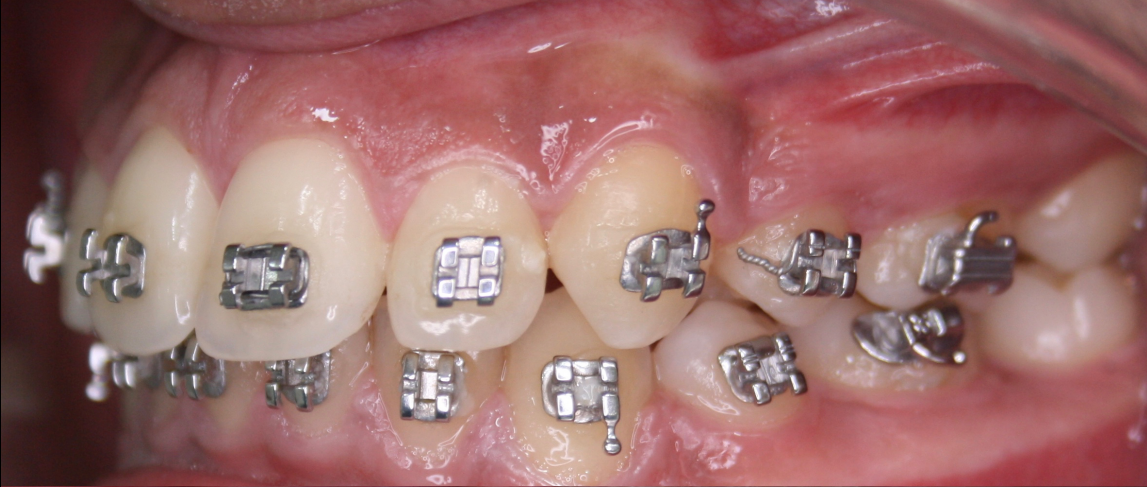PROFILE IMPROVEMENT



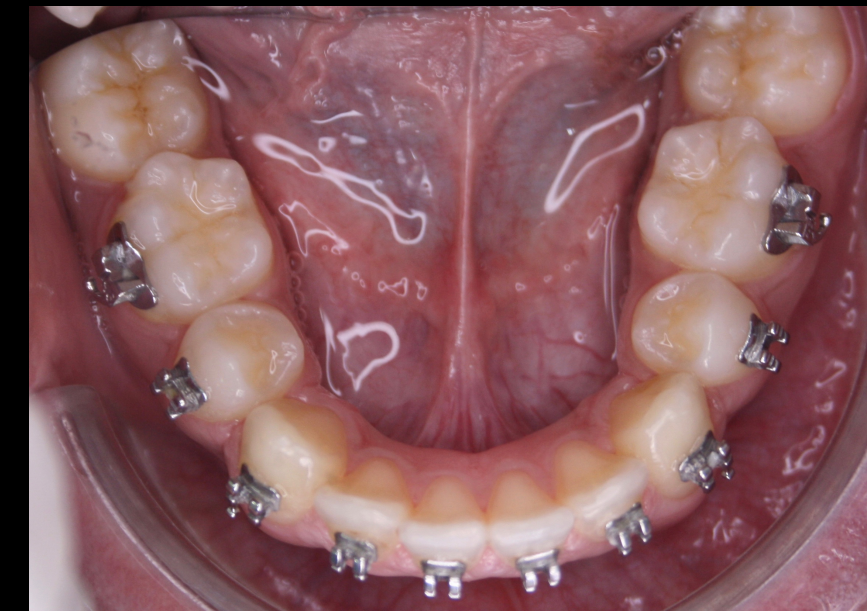BEFORE

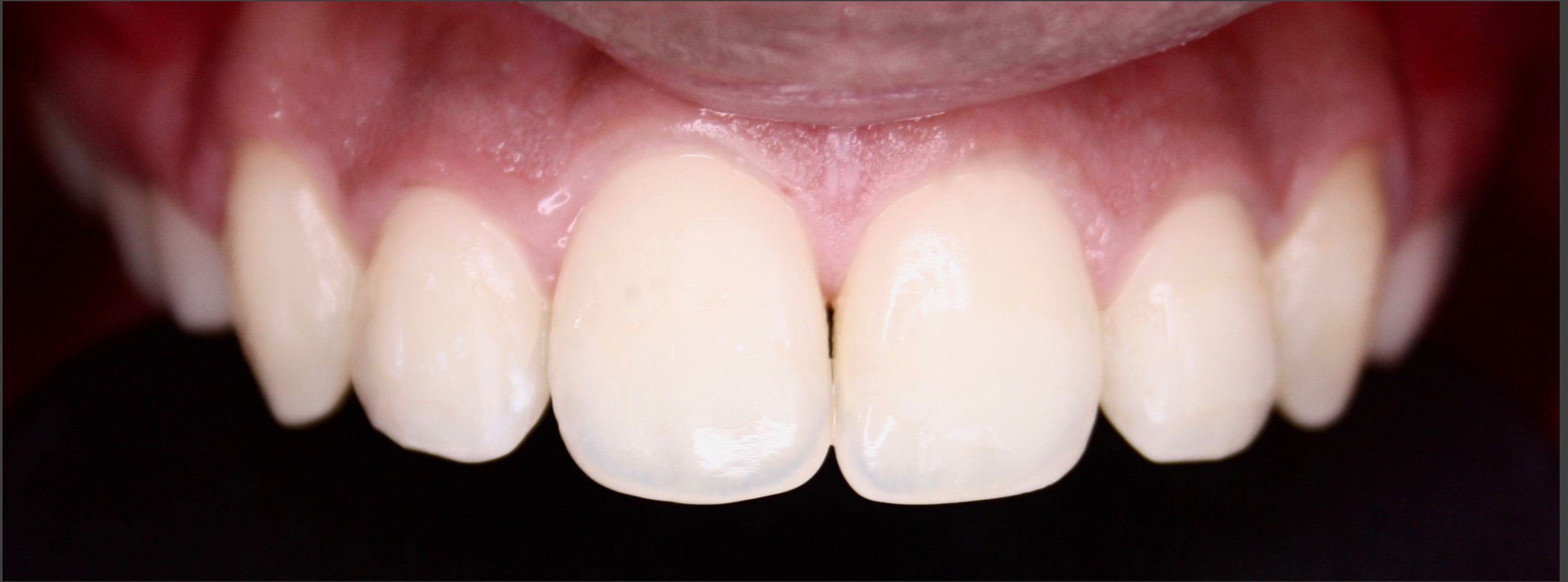

AFTER

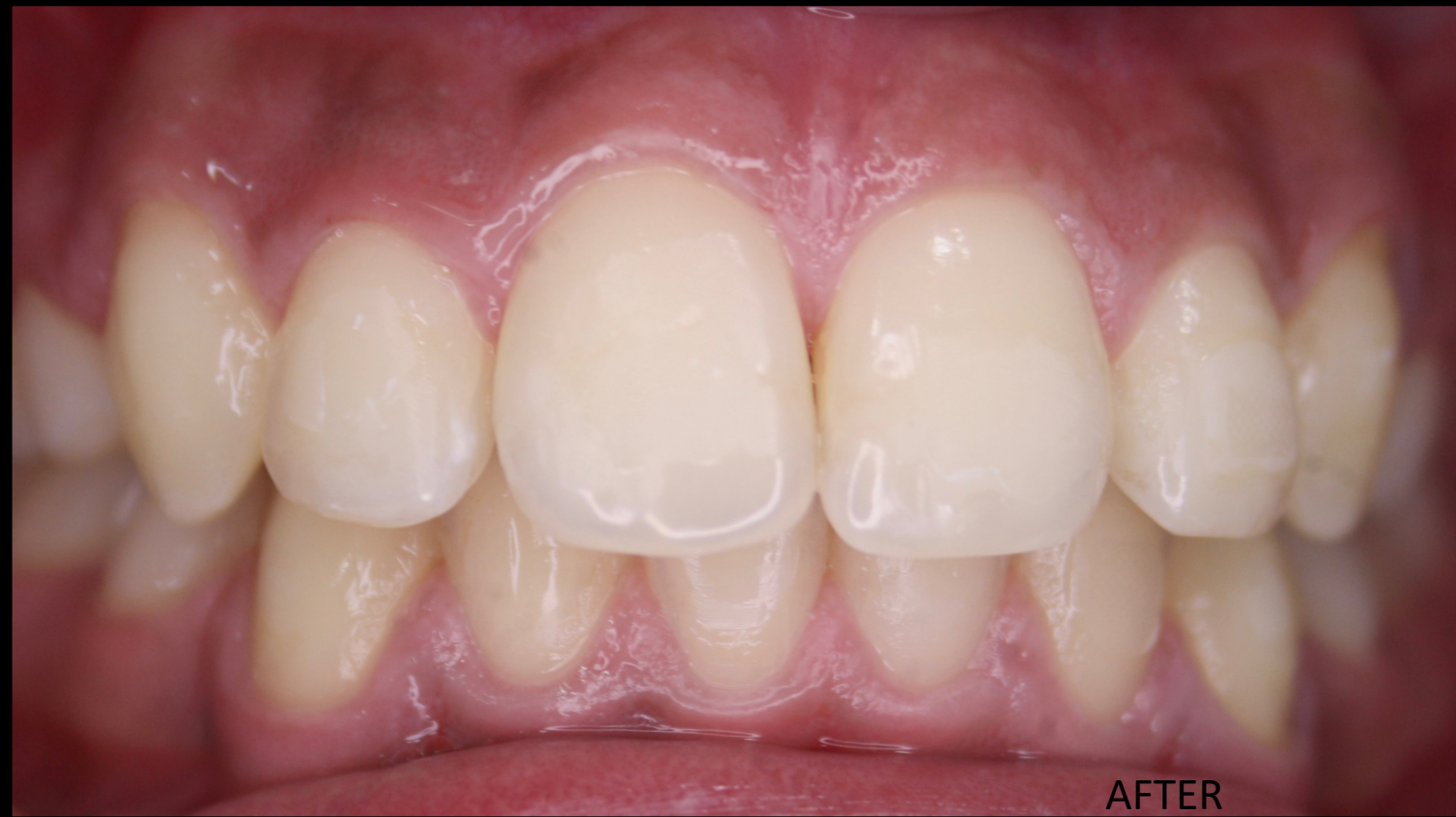
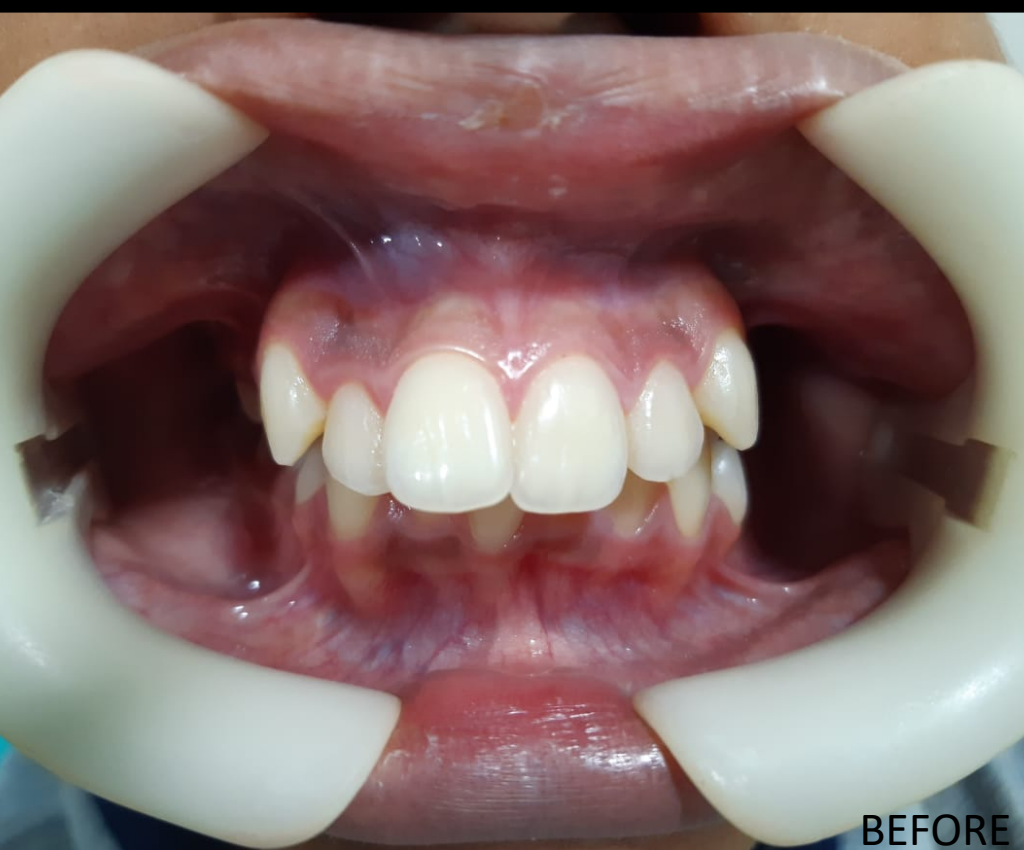
INTRA ORAL PHOTOS BEFORE DEBONDING



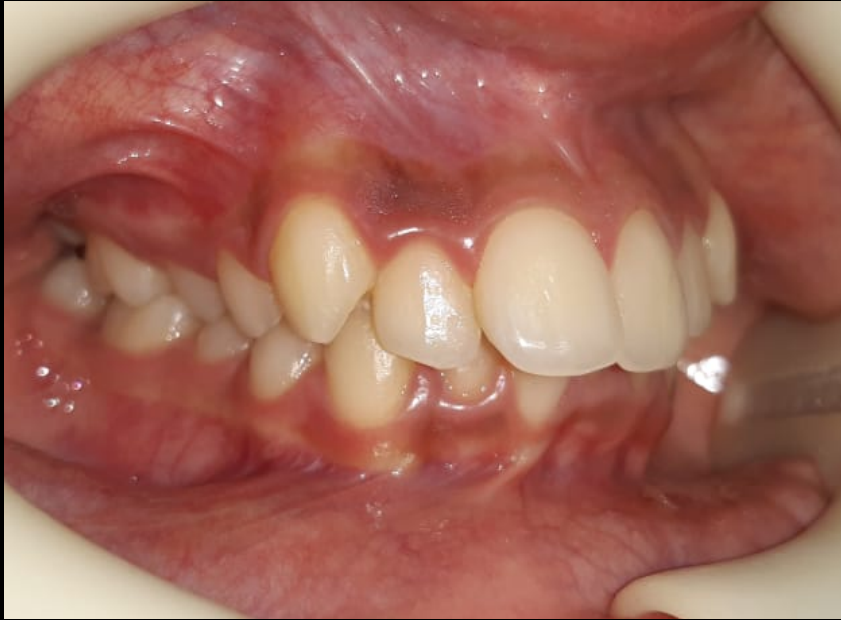

- MICRO ESTHETICS :
- SLIGHT GINGIVAL RECONTOURING WITH 21 WILL BE DONE LATER ON.
- LABIAL FRENCECTOMY IS ALSO PLANNED IN FUTURE.

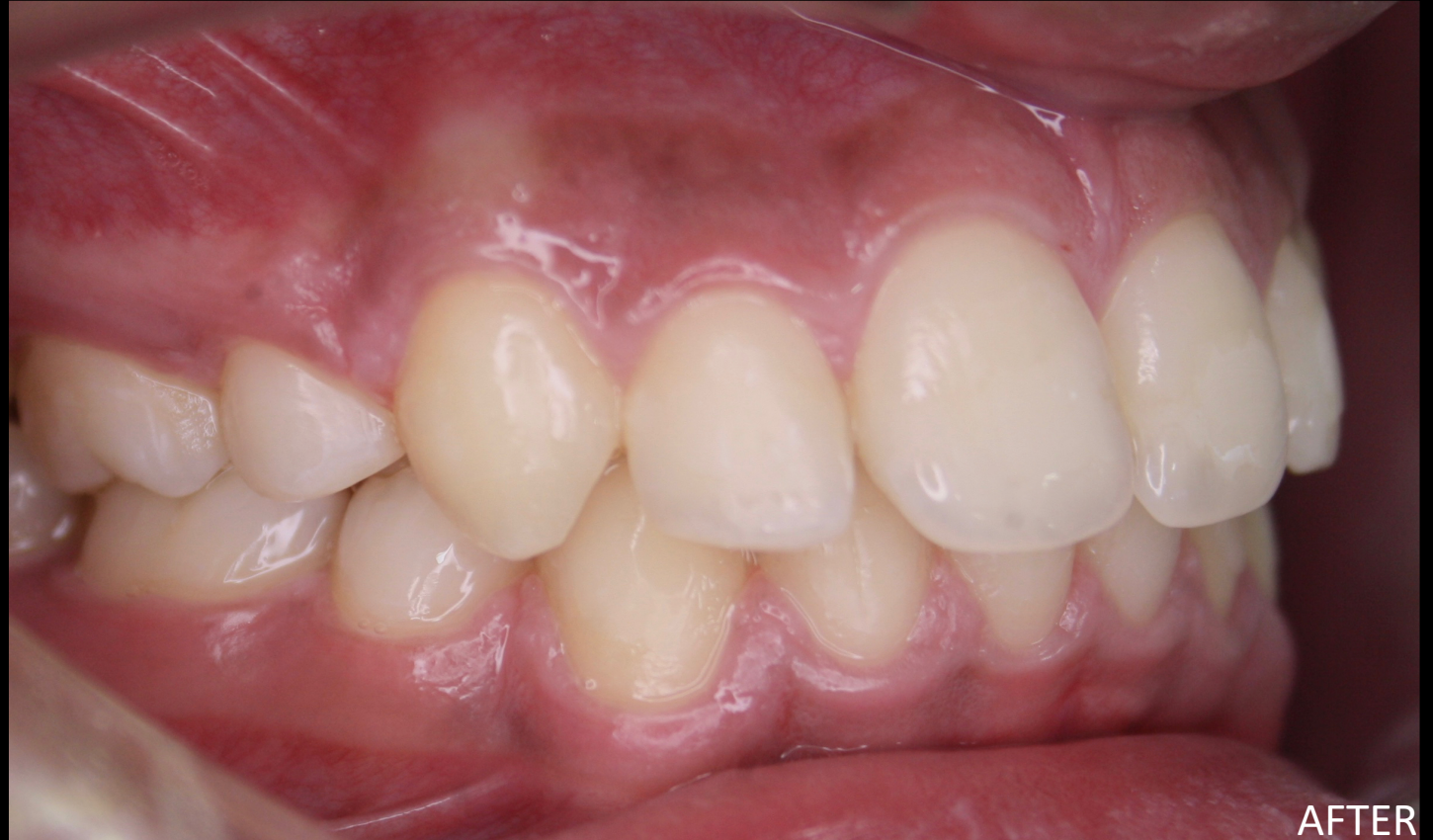

INTRA ORAL VIEW : FRONT

DEEP OVERBITE AND MIDLINE CORRECTION



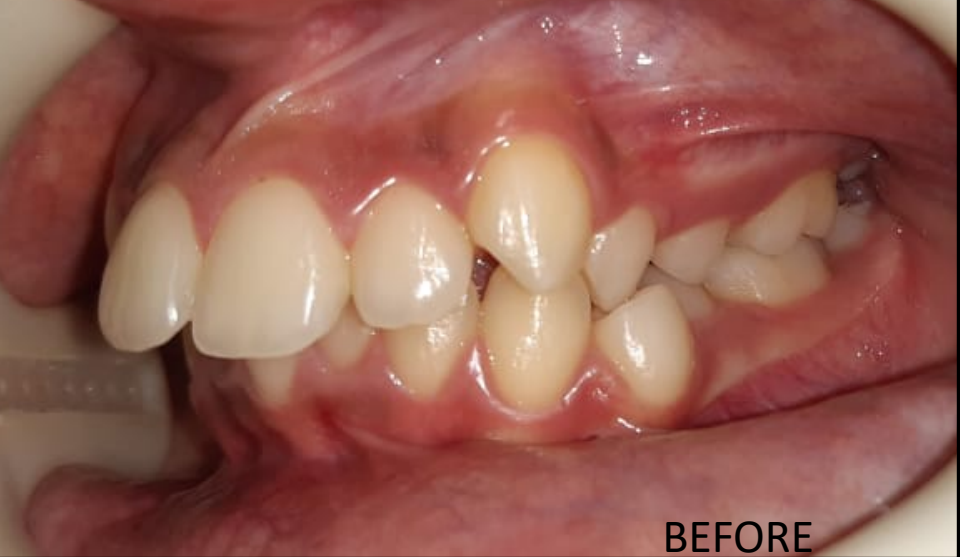BEFORE



AFTER

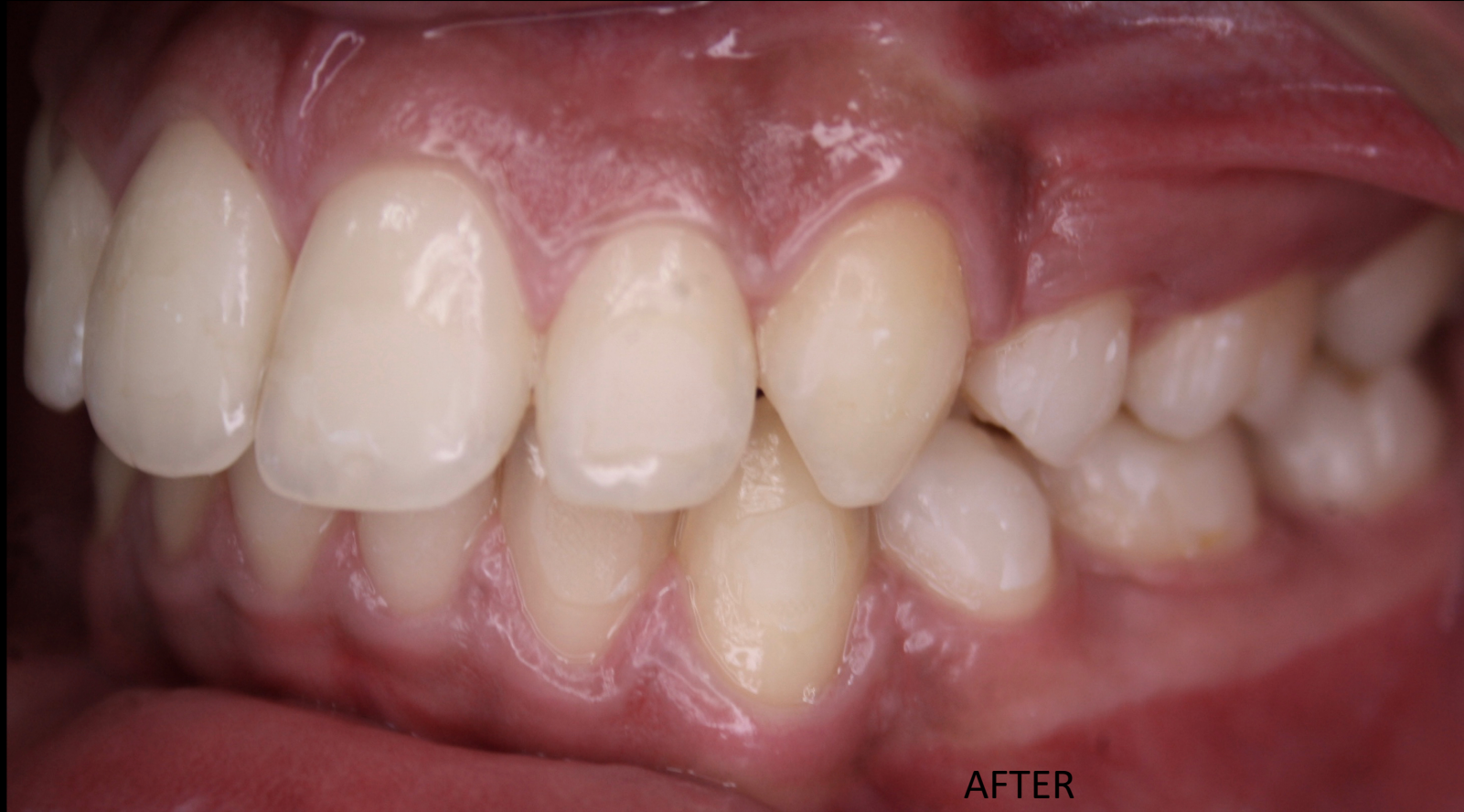RIGHT SIDE OCCLUSION

- EXCELLENT INTERCUSPATION

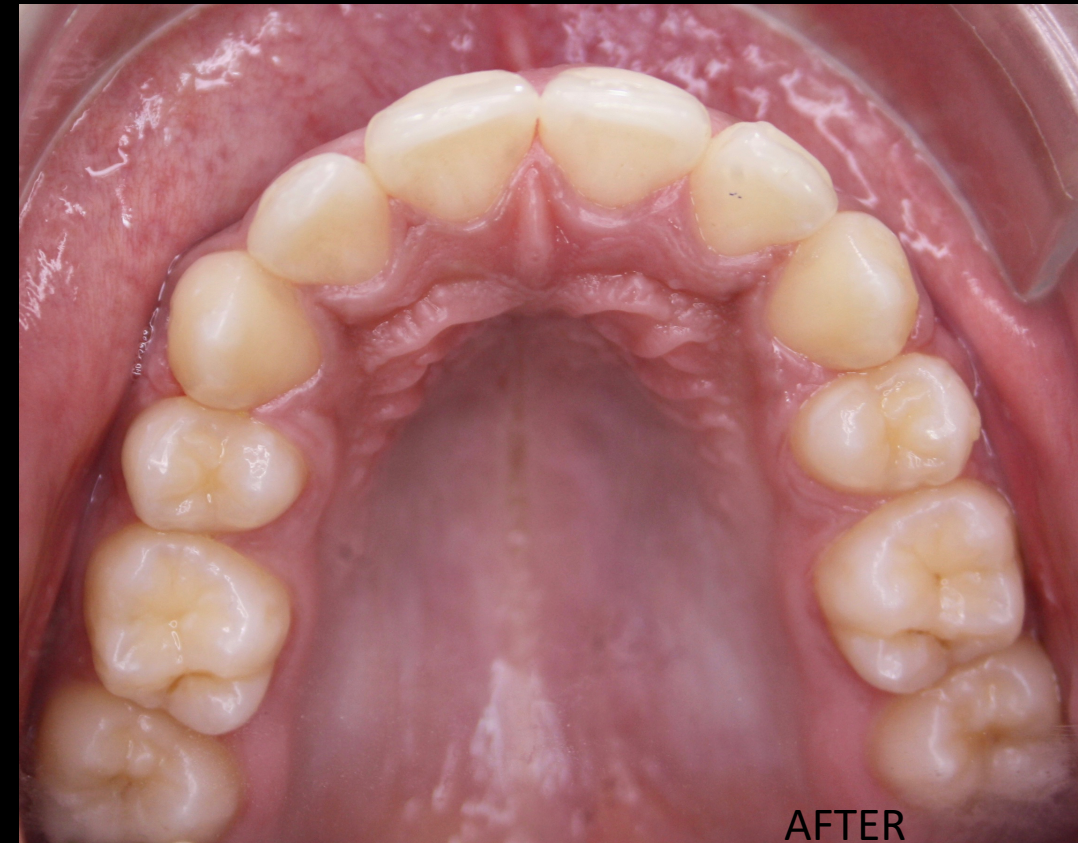
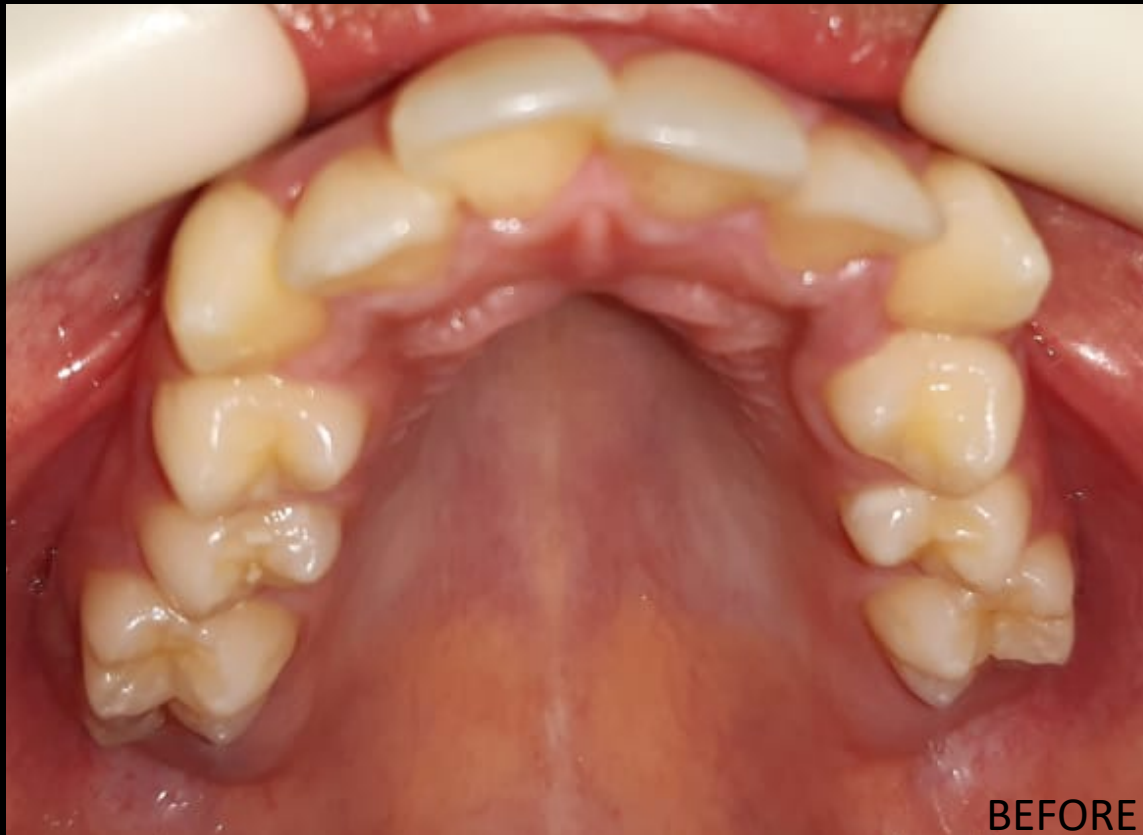
BEFORE

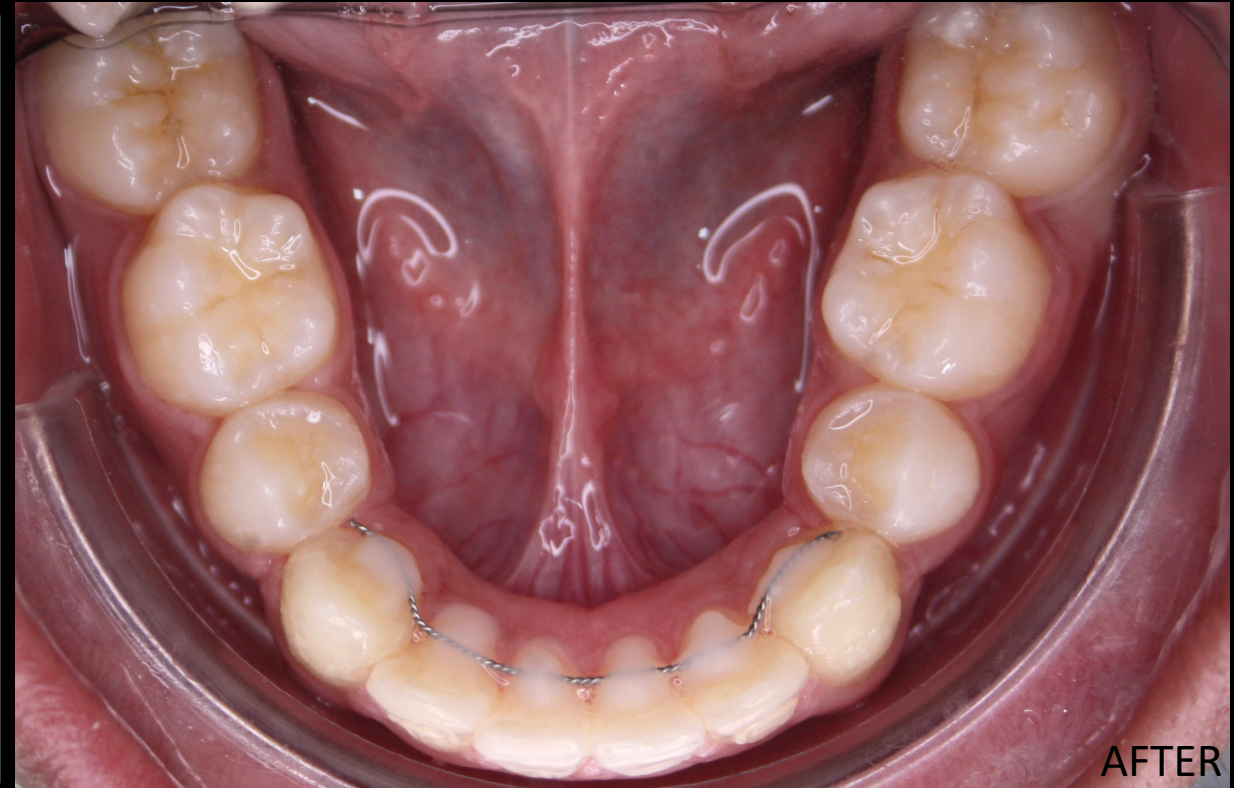
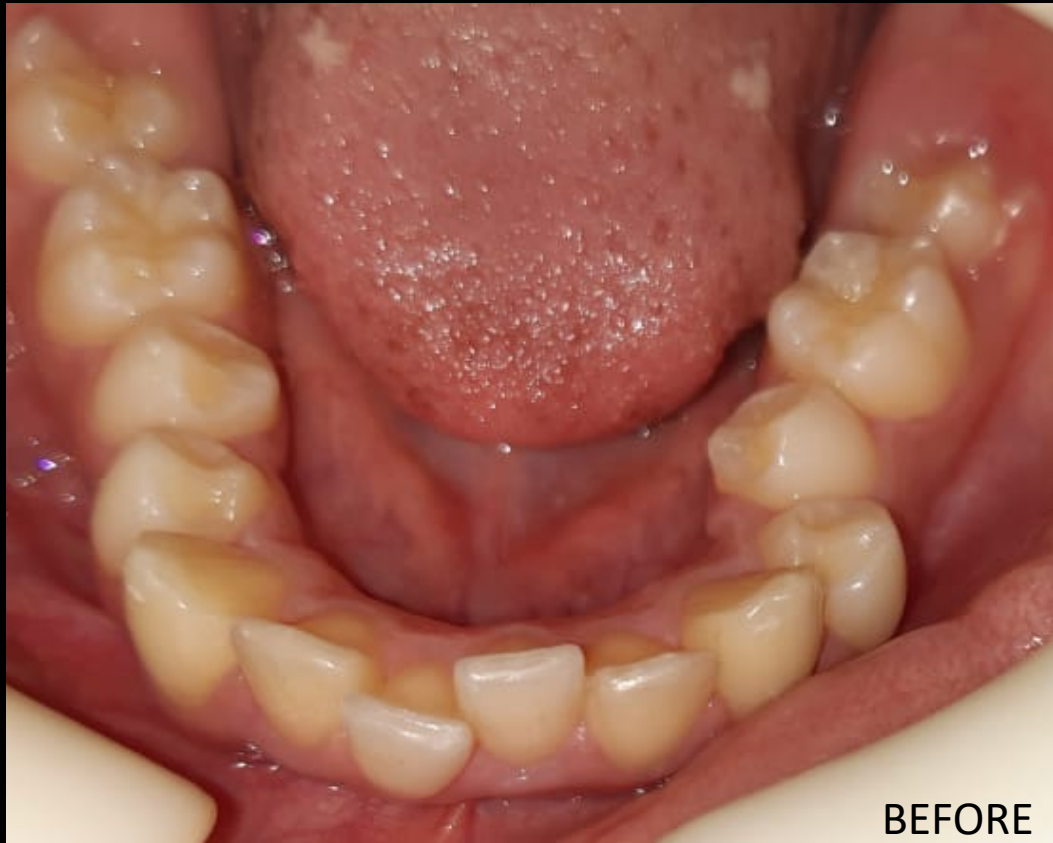
LEFT SIDE OCCLUSAL VIEW :
NOTICE, ENDON CANINE RELATION BEFORE



AFTER



OCCLUSAL VIEW: MAXILLARY ARCH



OCCLUSAL VIEW: MANDIBULAR ARCH